



QUIZ DE LA SEMAINE

Présenté par Dr **Boubaker Hamdi**




IMAGE CHALLENGE

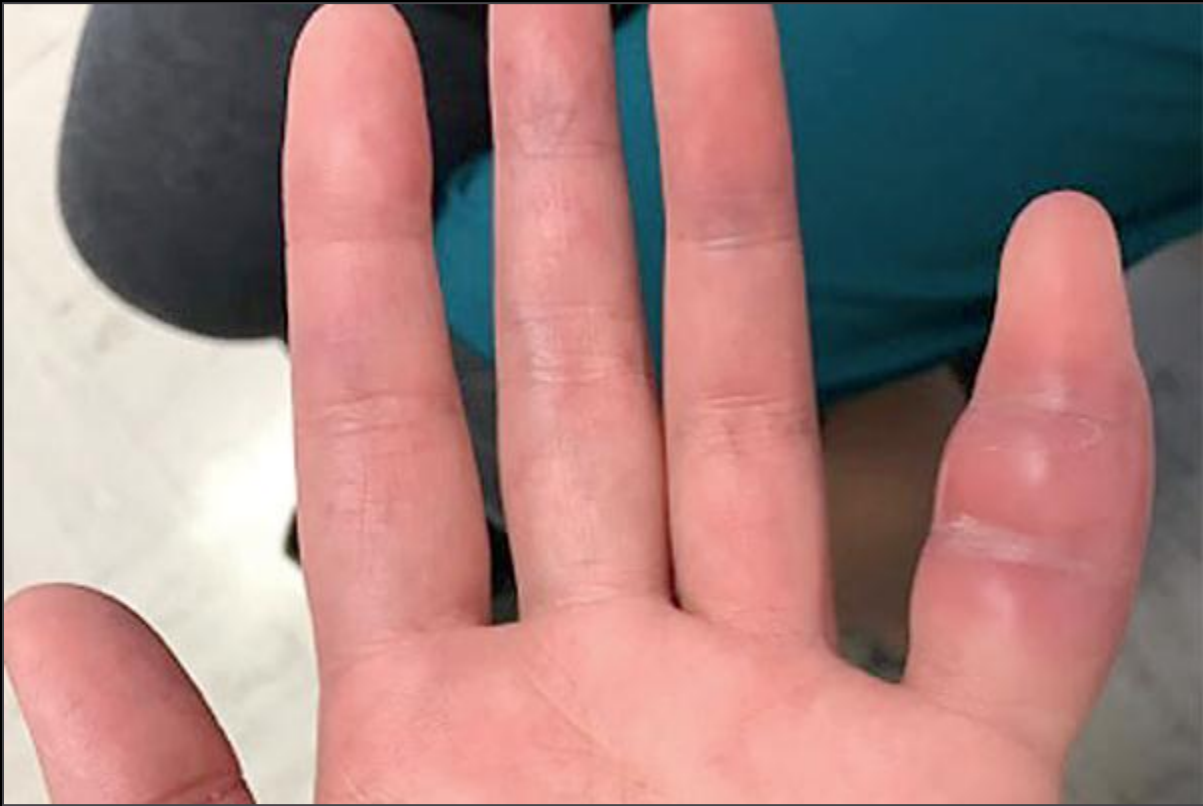



IMAGE CHALLENGE

Q: A 42-year-old woman presented with a 1-week history of swelling and pain in the fifth finger of her left hand. She reported no related trauma. She had systemic lupus erythematosus, treated with mycophenolate mofetil and prednisone. Physical examination of the affected finger revealed soft-tissue swelling, with erythema and warmth, that was most prominent between the proximal and distal interphalangeal joints, sparing the fingertip. The patient's husband had recently traveled to China and developed a cough soon after his return home. What is the cause of the patient's finger swelling?

1. Acute gout
2. Flare of systemic lupus erythematosus
3. Septic arthritis
4. Extrapulmonary manifestation of tuberculosis
5. Osteoarthritis